

## Gummy Smiles: Etiologies, Diagnoses & Formulating A Clinically Effective Treatment Protocol

**Sami Mohammed Saeed Alamri<sup>1</sup>, Faisal Saeed Salem Alshahrani<sup>2</sup>, Ibrahim Mohammed Abdulrahman Alshehri<sup>3</sup>, Mohammed Abdulaziz Ali Alobaydaa<sup>4</sup>, Wafaa Aiyd Abdallah Alhazri<sup>5</sup>, Suad Awadh Melfi Alanazi<sup>6</sup>, Sultan Mohammed Oudh Alganame<sup>7</sup>, Rayan Mohmoud Mohammed Eskandrani<sup>8</sup>**

<sup>1</sup>General Dentist, East Riyadh Dental Clinic Riyadh, Email: sami-alamri@hotmail.com

<sup>2</sup>General dentist, Hawtat Bani Tamim, Saudi Arabia, alriyadh, Email: drfaisalex1993@gmail.com

<sup>3</sup>general dentist, tiaf, makkah regional Email:bragg@gmail.com, colalaud

<sup>4</sup> Dentist, king kalad hospital in alkaraj, alkaraj-Saudi Email: alobayda1@gmail.com

<sup>5</sup>, Dentist, Saudi Ministry of Health, second cluster, Riyadh, Saudi Arabia Email: wafaalazri@hotmail.com

<sup>6</sup>Family Dental Medicine Specialist, Dental Center East Riyadh, Second Cluster, Ministry of Health, Riyadh, Saudi Arabia, Email: dr.su3ad@gmail.com

<sup>7</sup>General Dentist, Dental Hospital East Riyadh, Saudi Arabia, Email: salganame@moh.gov.sa

<sup>8</sup>restorative, ministry of health, Saudi Arabia / Riyadh, Email:  
dr.rayan.m.eskandrani@gmail.com

---

Received: 15.10.2024

Revised: 22.11.2024

Accepted: 11.12.2024

---

### ABSTRACT

The smile is the most accepted facial emotion that enhances a case's self-esteem, social skills, and capacity for interpersonal interaction. Excessive gingival exposure, commonly referred to as a gummy smile is a non-aesthetic disorder marked by an overexposure of the gingiva when smile. The demand from cases to address elevated smile lines has risen in recent years. This involves gingival overexposure, referred to as gummy smile or excess gingival show. A Smile by gums is a prevalent variant, particularly between females, with an occurrence rate of 10.5 to twenty-nine percent. Cases frequently possess insufficient awareness and knowledge concerning Botox treatments for gummy smiles; therefore, the clinician must thoroughly clarify all treatment alternatives and their potential effects with the case. Previous research has proposed classifying gummy grins according to their etiopathogenic variables to identify the most advantageous treatment option. These investigations indicate that a pronounced smile may be classified as dentoalveolar, resulting from excessive sagittal or vertical growth of the jaw; dentogingival, arising from alterations in the typical trajectory of dental eruption that diminish the clinical crown; muscular, because of excessive activity of the perioral musculature; or mixed, stemming from multiple etiological factors.

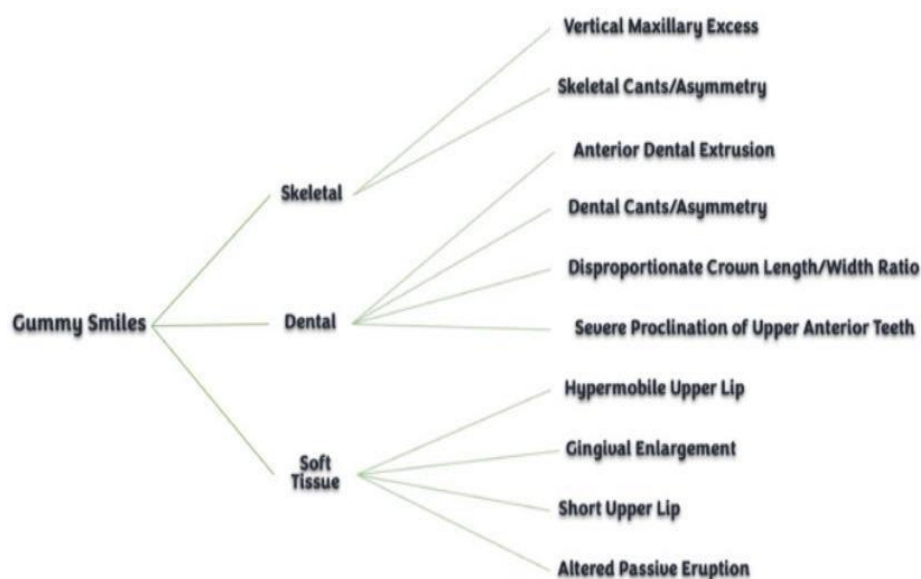
**Keywords:** Gummy Smiles, Botulinum toxin, diode dental laser

### INTRODUCTION

The smile is the prevalent accepted expression of face that enhances a case's self-esteem, community skills, & capacity for interpersonal interaction. Excessive gingival exposure, commonly referred to as a gummy smile is a non-aesthetic disorder marked by an overexposure of the gingiva while smiling. The demand from cases to address elevated smile lines has risen in recent years. This involves gingival overexposure, referred to as an extreme gingival show or gummy smile. A smile by gums is a prevalent distinction among the population, particularly among females, with an occurrence rate of 10.5%-29%.<sup>(1)</sup>

A gummy smile can be classified by intensity into mild (two to four millimeters of excessive gum exposure), moderate (four to eight millimeters), or severe (more than eight millimeters). In eighty-eight percent patients, it presents as a continuous band of gingival show in the anteroposterior orientation; nevertheless, it may be confined to posterior or anterior areas in exceptional occurrences. <sup>(2)</sup>

Upon identifying an anomaly in the smile's elevation, it is crucial to identify the underlying etiologies of a smile of gums. The etiology of a smile of gums is generally multifaceted, intricate, and often arises from a confluence of components categorized as Skeletal, Dental, and Soft Tissue (Fig. 1).



**Fig. 1.** Multifactorial etiology of smiles of gums / high gingival.

Various methods were documented to address gummy smiles, mostly include orthognathic operations, gingivectomy, botulinum toxin A injections (Botox), & lip repositioning. (3)

The preferred treatment is contingent upon etiological characteristics including skeletal problems, shortened anterior crowns, and muscle hyperactivity. The predominant cause of gummy grins is attributed to the hyperactivity of muscles of upper lips. Smiles of gum resulting from lip dynamics were effectively addressed with the application of Botox, which diminishes the upward movement of the lip. Altering lip positioning as well as movement with Botox is deemed an appropriate option because of its minimal morbidity and ease of application. Prior research addressed the management of gummy grins with the application of botulinum toxin; yet most of these investigations utilized varying methodologies based on injection sites and dosage modifications. (4)

### Different treatment approach

Cases frequently possess insufficient awareness and knowledge concerning Botox treatments for gummy smiles; therefore, the therapist must thoroughly clarify any therapy alternatives and their potential effects with the case. Previous research has indicated that classifying gummy grins according to their etiopathogenic characteristics is essential for identifying the most effective treatment strategy. These investigations indicate that a pronounced smile may be classified as dentoalveolar, resulting from excessive sagittal or vertical growth of the maxilla; dentogingival, arising from alterations in the typical trajectory of dental eruption that diminish clinical crown; muscular, because of over activity of the perioral muscles; or mixed, resulting from multiple etiological factors. Furthermore, this research indicated that many photometric & clinical factors must be evaluated from both the lateral and frontal views during the case smiles. (5)

The central incisors height typically varies from 9.5 - 11 millimeters, depending on the case's sex. If the case exhibits extreme gingiva resulting from small incisors, a referral to a periodontist is typically subsequent course of action to address the smile. Therefore, administering Botox injections to a casewith excessive gingival display resulting from crown exposure is unacceptable. (6)

Structural, dento-gingivo-labial, & occlusal factors must also be assessed throughout the therapy planning phase. Structural criteria encompass the edge of cutting incisal of incisors& the distance among subnasal points. Dento-gingivo-labial characteristics involve the gap of interlabial, the upper lip dimension, and coronal crown length. Occlusal factors involve the overjet inclination, overbite, & occlusal plane. Botox may serve as palliative when operation is required, as adjuvant therapy when supplementary treatments like orthodontic devices or augmentation of lips are necessary, or as remedial when the reason of excessive gingival show is muscular in origin. (7)

The gummy grin resulting from vertical maxillary excess can be addressed with orthognathic operation, requiring hospitalization & potentially leading to significant morbidity, making it undesirable for certain cases. Hyperactivity of the labial elevator muscles (levatorangulioris, zygomaticus minor, levator labii superioris and orbicularis oris) is an additional etiology of a smile of gums which could be addressed with one of the smallest invasive therapies available, namely, injection of botulinum toxin. When injected intramuscularly, the toxin inhibits acetylcholine release by cleaving synaptosome-associated protein-25

(SNAP-25), resulting in partial chemical muscle denervation. (8)

The consequence of this localized relaxation of activity of muscle is a limited action of pulling-up of lip throughout smiling. The effects of injections of botulinum toxin become evident within one to two weeks and typically persist for four to six months. It was suggested that numerous injections may result in prolonged muscle paralysis, hence causing sustained gingival exposure reduction, even following the toxin was metabolized. Botulinum toxin is often safe when administered correctly and in appropriate dosages. Nonetheless, side events such as asymmetrical smile, speech difficulties, challenges in chewing or pain, infection, drinking, hematoma or bruising, edema, inflammation, diminished strength of muscles, & nerve palsy were documented. (9)

The primary concern with botulinum toxin therapy is the requirement for several injections, spaced from four to six months apart. Esthetic crown lengthening is a method utilized to rectify excessive gingival display by reinstating natural dentogingival relationship, resulting in functional enhancement. The decision to increase it with osseous resection is based upon the existing biological width at the operative site. A simple gingivectomy isn't advisable when the level of crestal bone is near the cemento-enamel junction, as it can compromise the gingival attachment biologic width. Under these conditions, a complete thickness periodontal flap accompanied by osteotomy must be conducted. (10)

In 1973, Rubinstein and Kostianovsky described a lip repositioning operation for the treatment of gummy grin, subsequently reported by Litton and Fournier, as well as Miskinyar and Robbins. In 2006, Rosenblatt & Simon changed it & showed it to dentists. This operation is proposed as a conventional, permanent solution that necessitates a less invasive approach compared to orthognathic operation. The objective is to restrict the use of the muscles associated with smiling (levator angulioris, zygomaticus minor, orbicularis oris, & levator labii superioris) by reducing the upper vestibule depth. (11-16)

The original approach involved creating an elliptical incision within the vestibule, with a lower incision positioned three to four millimeters from the teeth of gingival edge, & an upper incision located at a distance twice that of the gingival exhibit. A gap of ten to twelve millimeters has been preserved among the lower & upper incisions. The initial technique didn't require muscle detachment following flap reflection; nevertheless, certain authors advocate for myectomies to separate the muscle attachments needed for smiling. (17)

Another method for elevating the smile muscles attachments involves the utilization of an autogenous or alloplastic separator. This spacer is inserted via a nasal route among anterior nasal spine & lip elevator muscles to prevent superior displacement of the relocated lip. (18)

Lasers are extensively utilized in dentistry for soft tissue applications, such as diode, or CO<sub>2</sub> lasers, neodymium yttrium aluminium garnet (YAG), and for hard tissue applications, such as erbium-doped yttrium aluminium garnet lasers. Soft-tissue applications encompass sulcular debridement, biostimulation, frenectomies, gingival peeling, gingivectomy, and biopsies. The application of lasers allows more efficient treatment as well as superior healing options compared to traditional surgical techniques employing scalpels. A prevalent application of lasers is utilizing diode lasers with wavelengths of 655–980 nanometers in laser gingivectomy procedures for cases with short clinical crowns, aimed at reducing the gingival sulcus. (19)

Gingivectomy is an operation that involves the excision of excess unsupported tissue of gingiva to a level where it is attached, so establishing a novel gingival edge that is apical to the previous location, without cooperating upon biological width. (20)

Aida M. Mossaad et al. studied a population primarily composed of female cases, consistent with multiple investigations in the field of esthetic dentistry. While some research compares male-to-female outcomes, this investigation indicates that Egyptian men exhibit fewer demand for esthetic treatment compared to women. (21) Numerous physicians utilized diverse methods to address the bothersome GS issues for their cases, including repositioning of lip, aesthetic crown lengthening, as well as gingival depigmentation; a thorough plan for a transformation of GS & transplantation of micro-autologous fat, as well as orthognathic procedures requiring general anesthesia as well as extensive bony osteosynthesis. Moreover, with GS measures, there must be advanced methodologies for assessing functional criteria for orthognathic operation, contingent upon several additional factors. Litton and Fournier utilized an alternative procedure involving the separation of muscles to retract the lip from the underlying bone structures. Simultaneously, in cases with GS, Silva et al. examined the repositioning of modified lip & reported favorable outcomes. Like techniques, nevertheless, might result in frequent recurrence & adverse effects, including contraction of wound. (22, 23).

Litton and Fournier implemented a procedure that involves lowering the lip through the separation of muscles from the underlying bone structures. Silva et al. examined the modified lip repositioning procedure in cases with gingival smile & stated favorable outcomes. Nonetheless, like procedures may result in recurrent recurrence and adverse effects, including scar constriction. The decision to provide laser gingivectomy or Botox injection for GS is based upon the underlying etiology and clinical assessment. (22, 23)

Rao et al. conducted a trial utilizing traditional surgical lip relocating, during which the labial frenum has been preserved, resulting in recurrence. A further investigation conducted by Dayakar et al. revealed that the conventional surgical LRS, which included the labial frenum, resulted in a complete recurrence following twelve

months.

Farista et al. previously compared the conventional approach to laser-assisted LRS in their research. The primary benefits of lasers in soft-tissue operation include a relatively bloodless operating field due to coagulation & decreased bacteremia, resulting in little pain following surgery. Moreover, a bloodless surgical area facilitates suturing, which is essential for operating success. (24-26)

A significant advantage of laser treatment is reduced pain following surgery. In comparison to the traditional scalpel approach, there is diminished intraoperative hemorrhage & decreased bacteremia, attributable to a sterile inflammatory state. An additional benefit of the laser was its high case acceptance, attributed to its simplicity & lower morbidity, with no following surgery drugs given apart from an as-needed medication. Nevertheless, a significant restriction associated with the operating method is the return of the smile of gums; our prior research noted a mild recurrence, prompting the implementation of a modified laser-assisted laser refractive surgery to address this issue. The advantages of modified laser-assisted laser refractive surgery compared to laser-assisted LRS are as follows: A partial-thickness flap can be excised using a laser instead of manually removing the mucosa. In laser-assisted laser refractive surgery, the excision of the mucosal strip was double the extent of the gingival tissue display requiring reduction, but in modified laser-assisted laser refractive surgery, an extra two millimeters of tissue has been excised to prevent relapse. In the enhanced laser-assisted laser refractive surgery, a laser bandage has been applied to facilitate healing and diminish inflammation and pain following surgery. (21)

## CONCLUSION

Botulinum toxin is regarded as a less invasive method for addressing gummy grins, especially caused by overactive lip muscles. Botulinum toxin can be efficiently utilized to treat gummy smiles resulting from lip dynamics, with infrequently observed consequences. The impact primarily occurs within one to two weeks, resulting in significant satisfaction among cases. The primary restriction of the procedure is the transient effect of Botox, lasting from four to six months; hence, re-injection of botulinum toxin is typically required. The diode dental laser is a safe, rapid, & successful surgical therapy that yields greater outcomes, whilst Botox injection is a swift, assured, and less intrusive approach to GS therapy that is favored by cases. The alteration of the lip repositioning method involves relocation the upper lip attachment more coronally, thereby relocating the mucogingival junction coronally instead of excising a strip of mucosa from the lip as well as suturing it back to its original site at the mucogingival junction. In its altered coronal position, the lip may hide portions of the gingiva throughout strong smiling, so increasing the patient's smile. Gingivectomy was conducted in instances of inflammatory, drug-induced, or, in rare occurrences, congenital gingival hypertrophy. Additionally, osteoplasty was effectively utilized to address GS.

## REFERENCES

1. Makkeiah MO, Harfoush M, Makkiah A, Saneeva L, Tuturov N, Katbeh I. Sravnitel'naya effektivnost' vvedeniya botoksa i kirurgicheskoi operatsii dlya korrektsii polozeniya gub pri desnevoiu lybke [Comparative efficacy of Botox and surgical lip repositioning in the correction of gummy smile]. *Stomatologiya (Mosk)*. 2021;100(3):47-54.
2. El-Bokle D, Ghany AH. A systematic diagnostic scheme for excessive gingival display "gummy smile". *AJO-DO Clinical Companion*. 2022 Aug 1;2(4):335-43.
3. Mazzucco R, Hessel D. Gummy smile and botulinum toxin: a new approach based on the gingival exposure area. *J Am Acad Dermatol*. 2010;63(6):1042-1051.
4. Bastidas JA. Surgical Correction of the "Gummy Smile". *Oral and Maxillofacial Surgery Clinics*. 2021 May 1;33(2):197-209.
5. Gracco A, Tracey S. Botox and the gummy smile. *Progress in orthodontics*. 2010 May 1;11(1):76-82.
6. Villarreal-Villarreal CD, Allen E, Kassir M. Gummy smile, dermatologist or dentist?. *Journal of the American Academy of Dermatology*. 2021 Mar 1;84(3):e127-9.
7. Rasteau S, Savoldelli C, Winter C, Lerhe B, Castillo L, Kestemont P. Botulinum toxin type A for the treatment of excessive gingival display—A systematic review. *Journal of stomatology, oral and maxillofacial surgery*. 2022 Nov 1;123(6):e717-23.
8. Ezquerro F, Berrazueta MJ, Ruiz-Capillas A, Arregui SJ, Carrera FE. New approach to the gummy smile. *Plastic and reconstructive surgery*. 1999 Sep 1;104(4):1143-50.
9. Polo M. Botulinum toxin type A (Botox) for the neuromuscular correction of excessive gingival display on smiling (gummy smile). *American journal of orthodontics and dentofacial orthopedics*. 2008 Feb 1;133(2):195-203.
10. Palomo L, Palomo JM, Bissada NF. Salient periodontal issues for the modern biologic orthodontist. In *Seminars in Orthodontics* 2008 Dec 1 (Vol. 14, No. 4, pp. 229-245). WB Saunders.
11. Pandurić DG, Blašković M, Brozović J, Sušić M. Surgical treatment of excessive gingival display using lip repositioning technique and laser gingivectomy as an alternative to orthognathic surgery. *Journal of oral and maxillofacial surgery*. 2014 Feb 1;72(2):404-e1.

12. Litton C, Fournier P. Simple surgical correction of the gummy smile. *Plastic and reconstructive surgery*. 1979 Mar 1;63(3):372-3.
13. Miskinyar SA. A new method for correcting a gummy smile. *Plastic and reconstructive surgery*. 1983 Sep 1;72(3):397-400.
14. Robbins JW. Differential diagnosis and treatment of excess gingival display. *Practical periodontics and aesthetic dentistry: PPAD*. 1999 Mar 1;11(2):265-72.
15. Rosenblatt A, Simon Z. Lip repositioning for reduction of excessive gingival display: a clinical report. *International Journal of Periodontics & Restorative Dentistry*. 2006 Oct 1;26(5).
16. Gupta KK, Srivastava A, Singhal R, Srivastava S. An innovative cosmetic technique called lip repositioning. *Journal of Indian Society of Periodontology*. 2010 Oct 1;14(4):266-9.
17. Rubinstein A, Kostianovsky A. Cosmetic surgery for the malformation of the laugh: original technique. *Prensa Med Argent*. 1973;60:952.
18. Ellenbogen R, Swara N. The improvement of the gummy smile using the implant spacer technique. *Annals of plastic surgery*. 1984 Jan 1;12(1):16-24.
19. Ganesh B, Burnice NK, Mahendra J, Vijayalakshmi R, K AK. Laser-Assisted Lip Repositioning With Smile Elevator Muscle Containment and Crown Lengthening for Gummy Smile: A Case Report. *Clinical advances in periodontics*. 2019 Sep;9(3):135-41.
20. Dym H, Pierre R. Diagnosis and treatment approaches to a "gummy smile". *Dent Clin North Am*. 2020 Apr 1;64(2):341-9.
21. Mossaad AM, Abdelrahman MA, Kotb AM, Alolayan AB, Elsayed SA. Gummy smile management using diode laser gingivectomy versus botulinum toxin injection-a prospective study. *Annals of maxillofacial surgery*. 2021 Jan 1;11(1):70-4.
22. Silva CO, Ribeiro-Júnior NV, Campos TV, Rodrigues JG, Tatakis DN. Excessive gingival display: treatment by a modified lip repositioning technique. *Journal of clinical periodontology*. 2013 Mar;40(3):260-5.
23. Litton C, Fournier P. Simple surgical correction of the gummy smile. *Plastic and reconstructive surgery*. 1979 Mar 1;63(3):372-3.
24. Cengiz AF, Goymen M, Akcali C. Efficacy of botulinum toxin for treating a gummy smile. *American Journal of Orthodontics and Dentofacial Orthopedics*. 2020 Jul 1;158(1):50-8.
25. Gupta P, Singh N, Tripathi T. Regarding "Efficacy of botulinum toxin for treating a gummy smile". *American Journal of Orthodontics and Dentofacial Orthopedics*. 2020 Dec 1;158(6):780.
26. Gibson MP, Tatakis DN. Treatment of gummy smile of multifactorial etiology: a case report. *Clinical advances in periodontics*. 2017 Nov;7(4):167-73.